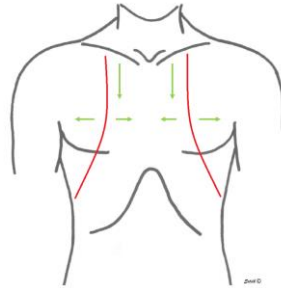
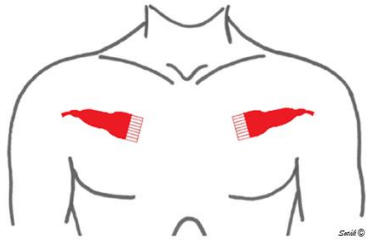




# Ultrazvuková diagnostika PNEUMOTHORAXU



## Normální nález

### B-mode:

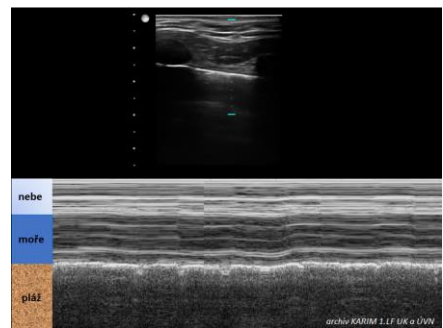
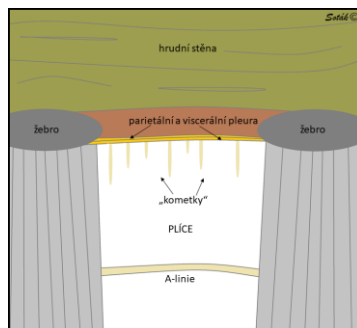
A-linie

„Lung sliding“

Kometky - “comet tails”

### M-mode:

„Seashore“ znamení



## Pneumothorax

### B-mode:

A-linie

Absence „Lung sliding“

Nejsou kometky - “comet tails”

„Lung point“

### M-mode:

„Barcode“ znamení

